


# Myocarditis following rAd26 and rAd5 vector-based COVID-19 vaccine: case report

Farah Naghashzadeh<sup>1</sup>, Shadi Shafaghi<sup>1</sup>, Atosa Dorudinia<sup>2</sup>, Seyed Alireza Naji<sup>3</sup>, Majid Marjani<sup>4</sup>, Ahmad Amin<sup>5</sup>, Arezoo Mohamadifar<sup>2\*</sup> , Sima Noorali<sup>1</sup> and Babak Sharif Kashani<sup>1,6</sup>

<sup>1</sup>Lung Transplantation Research Center, National Research Institute of Tuberculosis and Lung Diseases (NRITLD), Shahid Beheshti University of Medical Sciences, Tehran, Iran; <sup>2</sup>Chronic Respiratory Diseases Research Center, National Research Institute of Tuberculosis and Lung Diseases (NRITLD), Shahid Beheshti University of Medical Sciences, Tehran, Iran; <sup>3</sup>Virology Research Center, National Research Institute of Tuberculosis and Lung Diseases (NRITLD), Dr. Masih Daneshvari Hospital, Shahid Beheshti University of Medical Sciences, Tehran, Iran; <sup>4</sup>Clinical Tuberculosis and Epidemiology Research Center, National Research Institute of Tuberculosis and Lung Diseases (NRITLD), Shahid Beheshti University of Medical Sciences, Tehran, Iran; <sup>5</sup>Rajaie Cardiovascular Medical and Research Center, Iran University of Medical Sciences, Tehran, Iran; and <sup>6</sup>Tobacco Prevention and Control Research Center, National Research Institute of Tuberculosis and Lung Diseases (NRITLD), Shahid Beheshti University of Medical Sciences, Tehran, Iran

## Abstract

SARS-CoV-2 vaccines provide a safe solution with a major impact on reducing the spread of the virus and mild side effects. Research has shown rare cases of myocarditis after mRNA vaccines. This study presents a 29-year-old male with chest pain after 48 h of receiving rAd26 and rAd5 vector-based COVID-19 vaccine (Sputnik V vaccine). The electrocardiogram revealed ST-segment elevation. Also, the laboratory screening was remarkable for elevated cardiac Troponin-I level, and leukocytosis; and echocardiography depicted severe left ventricular systolic dysfunction. Overall, endomyocardial biopsy proved lymphocytic myocarditis such that the patient was successfully treated with immunosuppressive and guideline-directed medical treatment.

**Keywords** SARS-CoV-2; Gam-COVID-Vac; Sputnik V vaccine; Cardiovascular; Complication

Received: 4 June 2021; Revised: 29 December 2021; Accepted: 16 January 2022

\*Correspondence to: Arezoo Mohamadifar, Chronic Respiratory Diseases Research Center, National Research Institute of Tuberculosis and Lung Diseases (NRITLD), Shahid Beheshti University of Medical Sciences, Tehran, Iran. Tel: +98 9125365742, +98 21 27122522; Fax: +98 21 26109484. Email: arezoomohamadifar@yahoo.com

## Introduction

Following the outbreak of the COVID-19 pandemic, many efforts have been made to produce an effective vaccine to control the disaster. The vaccination programme against SARS-CoV-2 started in early December 2020 and has had a significant impact on reducing the spread of the virus and mortality.<sup>1,2</sup> Although vaccines are safe, technical workgroups of COVID-19 vaccine safety should assess vaccine safety data since the start of the vaccination programme.<sup>3</sup>

Meanwhile, few cases of myocarditis after mRNA COVID-19 vaccines have been reported. To the best of our knowledge, there is not any report of myocarditis after the rAd26 and rAd5 vector-based COVID-19 vaccines. Collaboration between infectious diseases, cardiology, and rheumatology specialists is needed to guide diagnosis, treatment, and management of myocarditis. Although most cases of myocarditis post-COVID-19 vaccine appear to be mild, follow-up of cases seems necessary.

This report presents a case of myocarditis after the second dose of the heterologous rAd26 and rAd5 vector-based COVID-19 vaccine (Sputnik V COVID-19 vaccine) in a previously healthy 29-year-old man.

## Case report

A 29-year-old man presented to the Emergency Department with chest pain and generalized malaise. He was restless from the chest pain and described it as a feeling of pressure on his chest that worsens by inspiration. Two days earlier, he received the second dose of the Sputnik V COVID-19 vaccine. He was previously well, and his medical history was unremarkable. He did not drink alcohol or use illicit drugs. During the examination, he was afebrile and had a heart rate of 110 b.p.m., blood pressure of 95/60 mmHg, and oxygen saturation of 95% on room air. The heart rhythm was sinus tachycardia, and S3

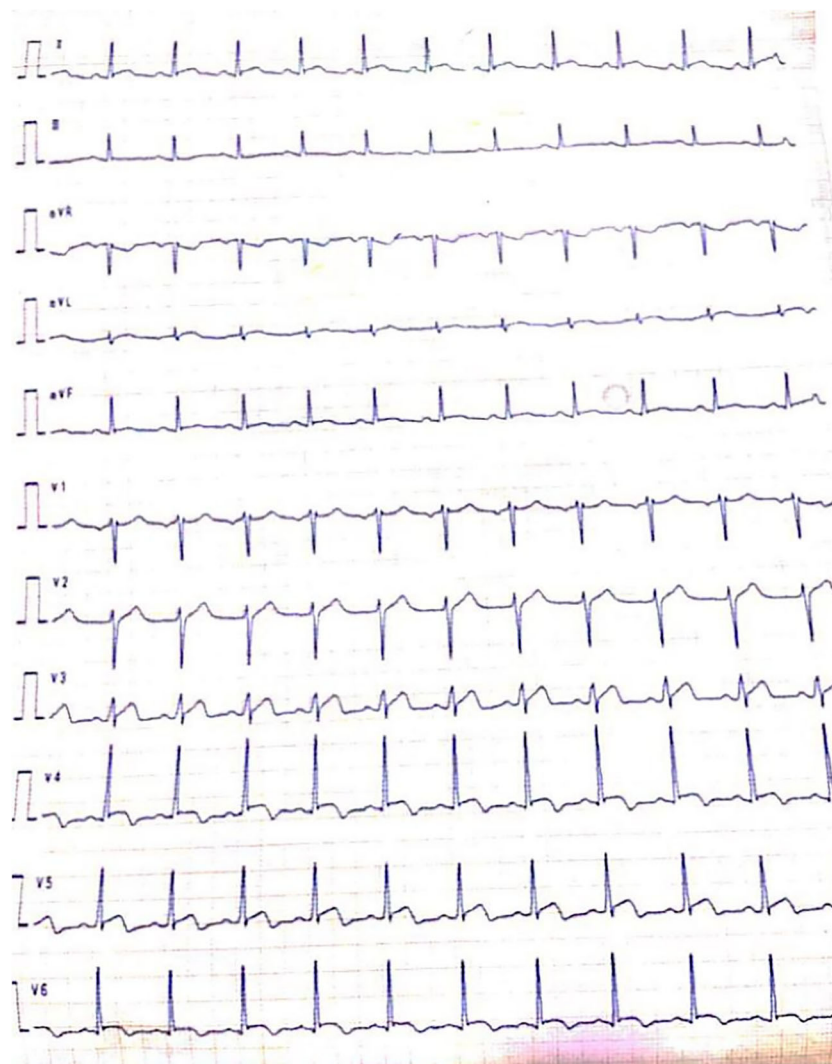was noted on auscultation. The jugular venous pressure was 5 cm of water. Vesicular breath sounds were heard in all lung fields. The patient had no swelling in his legs, and the remainder of the examination was unremarkable. An electrocardiogram (ECG) showed ST-segment elevation in precordial leads (V3–V4) (Figure 1). He was admitted to the cardiac care unit with a stable condition with no need for vasopressors, mechanical ventilators, or circulatory support. The peak Troponin-I level was 3.04 ng/mL (normal range: <0.02 ng/mL), white blood cell count of 13 500 per mm<sup>3</sup>, and normal C-reactive protein and erythrocyte sedimentation rate. In addition, two PCR of swabs taken from his upper respiratory tract returned negative for SARS-CoV-2 (Table 1). Meanwhile, the chest radiograph did not show any abnormal findings related to pneumonia, abscess, pulmonary oedema, lung masses, cavity lung lesions, pleural effusion, or any other abnormalities. Echocardiography indicated normal left ventricular (LV) size

**Table 1** Laboratory data

Variable	Values	Reference range
Haemoglobin (g/dL)	18.6	14.0–17.5
Haematocrit (%)	55.8	41.5–50.4
White cell count (per mm <sup>3</sup> )	13 500	4000–11 000
Platelet count (per mm <sup>3</sup> )	230 000	150 000–450 000
Sodium (mEq/L)	136	135–145
Potassium (mEq/L)	4.2	3.5–5.5
Urea nitrogen (mg/dL)	28	10–50
Creatinine (mg/dL)	0.9	0.9–1.3
Glucose (mg/dL)	94	70–100
Troponin-I (ng/mL)	3.04	<0.02
Calcium	8.3	8.6–10.3
Albumin (g/dL)	4.3	3.8–5.1
N-terminal pro-B-type natriuretic peptide (pg/mL)	320	<120
D-Dimer (ng/mL)	340	Negative <500
ESR (mm/h)	5	1–25
CRP (mg/L)	8	Up to 5
Lactate dehydrogenase	240	225–500

CRP, C-reactive protein; ESR, erythrocyte sedimentation rate.

**Figure 1** An electrocardiogram showed ST-segment elevation in precordial leads.



with global hypokinesia, LV ejection fraction (LVEF) of 30–35%, and increased LV wall thickness (12 mm). Also, the right ventricular systolic function was mildly impaired (Supporting Information, *Video S1*). No result was noticed regarding the presence of pericardial effusion. In addition, coronary angiography was pursued due to ST-segment elevation in the ECG, high Troponin-I, concern for the thrombotic acute coronary syndrome, and revealed patent epicardial coronary arteries with a slow flow of the left anterior descending artery.

*Table 2* presents the results of right heart catheterization. Due to the high suspicion of myocarditis, endomyocardial biopsy as the gold standard diagnostic test was performed during the angiography. Five tissue samples were taken from the right ventricular septum using Cordis biptome with a long sheath via right femoral vein access. Next, it was placed in 10% buffered formalin for histopathology survey and immunohistochemistry staining. Eventually, one sample was sent in a sterile Falcon tube for virology. Histopathological examination of endomyocardial biopsy specimens showed lymphocytic infiltration compatible with lymphocytic myocarditis (*Figure 2*). However, biopsy samples for viral PCR were detected negative for severe acute respiratory syndrome coronavirus 2 (SARS-CoV-2) and other viruses including Cytomegalovirus, Adenovirus, Human Herpes Virus-6 (HHV6), Parvovirus B19, Enterovirus, and Influenza A/B viruses. Moreover, serum PCR testings for coxsackievirus, hepatitis C virus, and human immunodeficiency virus were negative.

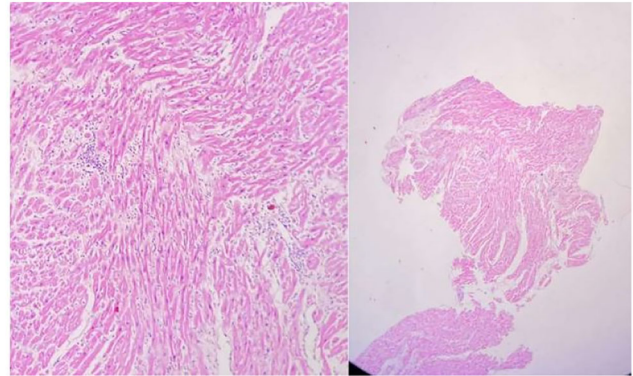
With the diagnosis of lymphocytic myocarditis, the immunosuppressive treatment was initiated with methylprednisolone, prednisolone, and mycophenolate mofetil. Also, a guideline-directed medical treatment was followed for heart failure in combination with enalapril, carvedilol, and spironolactone.<sup>4</sup>

After 2 days of immunosuppressive therapy, the LVEF improved to 50–55% (Supporting Information, *Video S2*), there was no chest pain, and serial troponins continued to fall such that it was <0.02 ng/mL at the time of discharge. Finally, the patient was discharged 7 days after admission. Post-hospital discharge follow-up for 4 months did not show any illnesses and echocardiography, and follow-up magnetic resonance imaging showed normal cardiac function.<sup>4</sup>

**Table 2** Right heart catheterization data

Variable	Values
Cardiac output, Fick method (L/min)	4.6
Cardiac index (L/min/m <sup>2</sup> )	2.4
Pulmonary artery pressure (mean) (mmHg)	18/10 (12.6)
Right ventricular pressure (mmHg)	18/0–5
Mean right atrium pressure (mmHg)	4
Pulmonary vascular resistance (Woods)	0.5
Systemic vascular resistance (Woods)	18.5
Systemic oxygen saturation (%)	95
Mixed venous oxygen saturation (%)	79

**Figure 2** Histopathological examination of endomyocardial biopsy specimens showed lymphocytic infiltration, compatible with lymphocytic myocarditis.



## Discussion

COVID-19 is a clinical syndrome caused by SARS-CoV-2 that primarily involves the respiratory system and is associated with cardiovascular features of myocardial involvement, including elevated serum troponin levels, myocarditis, and acute heart failure.<sup>5</sup> Although the prevalence of myocarditis in COVID-19 is unclear, a meta-analysis of autopsy studies by Halushka and Vander Heide suggests many cases at autopsy reporting non-specific inflammatory infiltrates may not be acute myocarditis. According to these authors, the incidence of acute myocarditis may be <2%. Therefore, myocarditis was probably not the cause of death in these patients.<sup>6</sup> The pathophysiology of COVID-19-related myocarditis is thought to be a combination of cardiac damage due to the host's immune response and direct SARS-CoV-2 injury.<sup>7</sup>

The literature shows no report of myocarditis after injecting rAd26 and rAd5 vector-based COVID-19 vaccines (Gam-COVID-Vac). Although we found some reports of acute myocarditis after administration of the second dose BNT162b2 vaccine against COVID-19, the definitive aetiological diagnosis was difficult to determine without evidence of myocardial inflammation in the endomyocardial biopsy.<sup>8</sup> Sputnik V is the world's first registered vaccine, and it has been approved for use in 71 countries with a total population of 4 billion people.<sup>9</sup> The number of the Sputnik V vaccine doses ordered worldwide as of March 2021 was 765 million, and about 800 000 doses have been injected in Iran.<sup>9</sup> Here, we report a case of myocarditis in a 29-year-old male who had no underlying medical conditions before the event. The symptoms started about 48 h after he received the second dose of the Sputnik V COVID-19 vaccine. These symptoms started shortly after the vaccination and raised the suspicion that an immunological reaction may have caused the lymphocytic myocarditis. This vaccine is a heterologous adenoviral vector-based vaccine against SARS-CoV-2

designed with two recombinant adenovirus vectors. According to an interim analysis of a randomized controlled phase 3 trial in Russia, the Sputnik V vaccine is safe and well tolerated. After injecting this vaccine, the most common adverse event was pain at the injection site, hypothermia, headache, and muscle and joint pain.<sup>3,10</sup>

Myocarditis is an extremely rare phenomenon that has been reported infrequently following the vaccine administration of influenza, smallpox, and the human papillomavirus. Generally, it is hard to explain the underlying mechanism because of its rarity.<sup>11–13</sup> Because SARS-CoV-2 mortality is high around the world, the development of a vaccine is an urgent task. Vaccination will restrict the spread of COVID-19 and reduce mortality. Given the abundant benefits of the COVID-19 vaccine, and the low incidence of clinically significant complications, we encourage immunization with vaccination. According to the myocarditis following the COVID-19 vaccine, ongoing surveillance is required to evaluate the occurrence of rare adverse events. Therefore, clinicians should be vigilant to provide prompt diagnosis and treatment for this purpose.

## Ethics approval

All procedures performed in studies involving human participants were following the ethical standards of the institutional and/or national research committee and with the 1964

Helsinki declaration and its later amendments or comparable ethical standards.

## Informed consent

Informed consent was obtained from the individual participant included in the study.

## Conflict of interest

The authors declare that they have no conflict of interest.

## Funding

This study was not supported by any funding.

## Supporting information

Additional supporting information may be found online in the Supporting Information section at the end of the article.

**Video S1.** Supporting Information

**Video S2.** Supporting Information

## References

- Rossmann H, Shilo S, Meir T, Gorfine M, Shalit U, Segal E. COVID-19 dynamics after a national immunization program in Israel. *Nat Med* Nature Publishing Group 2021; **27**: 1–7.
- Cook TM, Roberts JV. Impact of vaccination by priority group on UK deaths, hospital admissions and intensive care admissions from COVID-19. *Anaesthesia* Wiley Online Library 2021; **76**: 608–616.
- Jones I, Roy P. Sputnik V COVID-19 vaccine candidate appears safe and effective. *Lancet* Elsevier 2021; **397**: 642–643.
- Ponikowski P, Voors AA, Anker SD, Bueno H, Cleland JGF, Coats AJS, Falk V, González-Juanatey JR, Harjola V-P, Jankowska EA. 2016 ESC Guidelines for the diagnosis and treatment of acute and chronic heart failure: the Task Force for the diagnosis and treatment of acute and chronic heart failure of the European Society of Cardiology (ESC) Developed with the special contribution of the Heart Failure Association (HFA) of the ESC. *Eur Heart J* Oxford University Press 2016; **37**: 2129–2200.
- Basso C, Leone O, Rizzo S, De Gaspari M, van der Wal AC, Aubry M-C, Bois MC, Lin PT, Maleszewski JJ, Stone JR. Pathological features of COVID-19-associated myocardial injury: a multicentre cardiovascular pathology study. *Eur Heart J* 2020; **41**: 3827–3835.
- Halushka MK, Vander Heide RS. Myocarditis is rare in COVID-19 autopsies: cardiovascular findings across 277 post-mortem examinations. *Cardiovasc Pathol* Elsevier Inc. 2021; **50**: 107300.
- Siripanthong B, Nazarian S, Muser D, Deo R, Santangeli P, Khanji MY, Cooper LT Jr, Chahal CAA. Recognizing COVID-19-related myocarditis: the possible pathophysiology and proposed guideline for diagnosis and management. *Heart Rhythm* Elsevier 2020; **17**: 1463–1471.
- Bautista García J, Peña Ortega P, Bonilla Fernández JA, Cárdenes León A, Ramírez Burgos L, Caballero Dorta E. Acute myocarditis after administration of the BNT162b2 vaccine against COVID-19. *Rev Esp Cardiol*. Spain 2021; **74**: 812–814.
- <https://sputnikvaccine.com/about-vaccine/>
- Logunov DY, Dolzhikova IV, Shcheplyakov DV, Tukhvatulin AI, Zubkova OV, Dzharullaeva AS, Kovyrshina AV, Lubenets NL, Grousova DM, Erokhova AS. Safety and efficacy of an rAd26 and rAd5 vector-based heterologous prime-boost COVID-19 vaccine: an interim analysis of a randomised controlled phase 3 trial in Russia. *Lancet* Elsevier 2021; **397**: 671–681.
- Mei R, Raschi E, Forcesi E, Diemberger I, De Ponti F, Poluzzi E. Myocarditis and pericarditis after immunization: gaining insights through the Vaccine Adverse Event Reporting System. *Int J Cardiol* Elsevier 2018; **273**: 183–186.
- Kim Y-J, Bae J-I, Ryoo SM, Kim WY. Acute fulminant myocarditis following influenza vaccination requiring extracorporeal membrane oxygenation. *Acute Crit Care* Korean Society of Critical Care Medicine 2019; **34**: 165–169.
- Cheng MP, Kozoriz MG, Ahmadi AA, Kelsall J, Paquette K, Onrot JM. Post-vaccination myositis and myocarditis in a previously healthy male. *Allergy Asthma Clin Immunol* BioMed Central 2016; **12**: 1–6.